

WHRIA
Women's Health & Research Institute of Australia

**Pelvic and Perineal Pain:
Beyond Endometriosis and Pregnancy**

Jason Chow

The Royal HOSPITAL FOR WOMEN
Prince of Wales PRIVATE HOSPITAL

1


WHRIA
Women's Health & Research Institute of Australia

Heartsink!



2

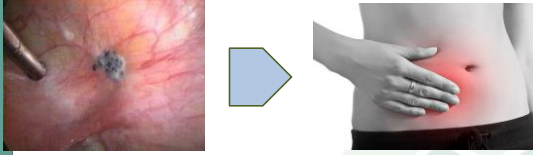
WHRIA
Women's Health & Research Institute of Australia



3


WHRIA
Women's Health & Research Institute of Australia

Background




4

WHRIA
Women's Health & Research Institute of Australia



5

WHRIA
Women's Health & Research Institute of Australia




6

WHRIA

Surgery

- 20% no response to surgery
- 32% placebo response



Abbott et al 2004

- 1st surgery 83% reduction in pain
- 2nd surgery 53% reduction in pain

- 20% recurrence disease

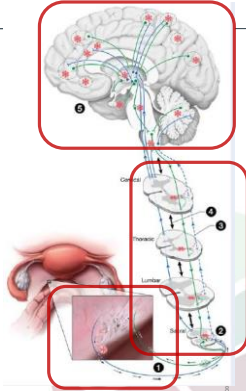
Vercellini et al 2009

7

WHRIA

More...

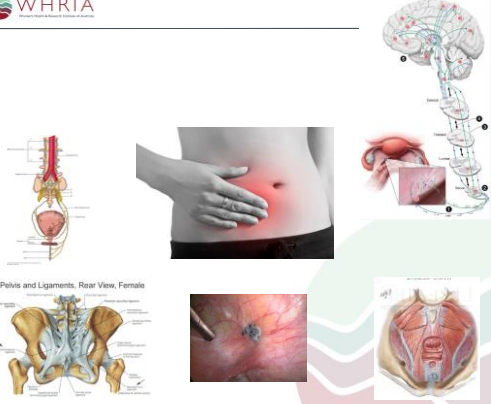
- Nerve fibres
- Sensitisation
 - Cross sensitisation
 - Central sensitisation
- Prostaglandins
 - Anti-angiogenic
 - Anti-inflammatory
 - Immunomodulatory



Stratton and Berkley 2011
Fenton 2007

8

WHRIA



Pelvis and Ligaments, Rear View, Female

10

WHRIA

Challenge

- Central mechanisms
- Peripheral triggers
 - Not just visceral based
- Psychological effects
- Functional effects

10

WHRIA Case 1

Natalie

- 25yo
- G0
- Dysmenorrhoea
- Non menstrual pelvic pain
- Dyschezia
- Chronic neck pain
 - Work - Bunning's
- Same sex
 - No current partner
- Ultrasound - normal

11

WHRIA Case 1: Natalie

Assessment

- Normal neurological exam
- No pelvic girdle tenderness
- Abdominal wall hyperaesthesia
- High tender cul de sac
- Pelvic floor myalgia

12

WHRIA
WOMEN'S HEALTH RESEARCH IN AUSTRALIA

Case 1: Natalie

Management

- Amitriptyline
- NSAIDs
- COCP
- Opioids?
 - Tapentadol
 - Buprenorphine
- Physiotherapy
- Internet based CBT
- Laparoscopy

13

WHRIA
WOMEN'S HEALTH RESEARCH IN AUSTRALIA

Case 1: Natalie

Management

- Improvement
 - Dysmenorrhoea
 - NMPP
 - Neck pain
- Dyschezia predominant
- Laparoscopy
 - Stage 3 endometriosis
 - Pararectal space
 - Weaning Endep at 6 months
 - Physiotherapy

14

WHRIA
WOMEN'S HEALTH RESEARCH IN AUSTRALIA

15

WHRIA
WOMEN'S HEALTH RESEARCH IN AUSTRALIA

Case 2: Melissa

Pregnancy

- 31yo
- G1P1 6 months postpartum
- LSCS
- Right sided abdominal pain
- Sacral pain
- Apareunia

16

WHRIA
WOMEN'S HEALTH RESEARCH IN AUSTRALIA

Pregnancy

- Challenging!
- Pain is not normal
- Unexplained
 - Visceral bias
- Early recognition
- Multifactorial

17

WHRIA
WOMEN'S HEALTH RESEARCH IN AUSTRALIA

Persistent Postpartum Pain

- Dyspareunia
- Pelvic girdle
- Coccyx
- Neuralgia
 - Perineal tear/episiotomy
 - Caesarean

18

WHRIA
WOMEN'S HEALTH REHABILITATION IN AUSTRALIA

Red Flags

- Infection
- VTE
- Neurological
- Sacral fractures
 - Osteoporosis
- Postnatal depression

19

WHRIA
WOMEN'S HEALTH REHABILITATION IN AUSTRALIA

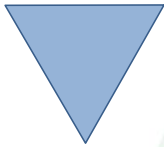
Pelvic Girdle Pain

- Between PSIS and gluteal fold
- Posterior thigh
- Reduced ability to stand/walk/sit
- Exclude lumbar causes

20

WHRIA
WOMEN'S HEALTH REHABILITATION IN AUSTRALIA

Abdominal Wall Pelvic Girdle



Pelvic Floor

21

WHRIA
WOMEN'S HEALTH REHABILITATION IN AUSTRALIA

Postpartum

Dyspareunia

- Hypo oestrogenism
- Skin split
- Cotton tip
- Single finger exam
- Pelvic floor
- Pudendal nerve


22

WHRIA
WOMEN'S HEALTH REHABILITATION IN AUSTRALIA

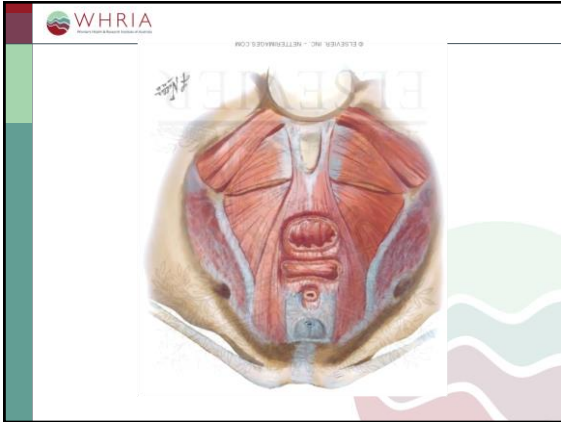


23

WHRIA
WOMEN'S HEALTH REHABILITATION IN AUSTRALIA



24



Postpartum

Wound Neuralgia

- ?Iliohipogastric/inguinal neuralgia
- Hip flexion
 - Getting out of bed
 - Stairs
- Finger test
 - Lateral border rectus

26

Postpartum

Management

- Prevention
 - Exercise in pregnancy
 - Mode of delivery?
- Physical therapy
 - Not just pelvic floor strength
- TENS

27

Postpartum

Management

- Paracetamol
- NSAIDs
- TCAs
- Topical
 - Oestriol
 - Amitryptiline
- Gabapentinoids
- Opioids

28

Postpartum

Management

- Focussed intervention
- Iliohipogastric/inguinal block
- Pudendal blocks
 - Hyaluronic acid
 - Pulsed radiofrequency
- Impar ganglion
- Fractional CO2 laser

29



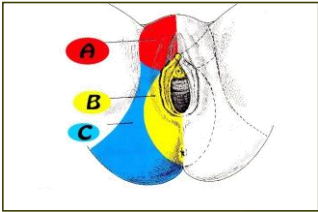
WHRIA Case 3

Helen

- 69yo
- Right labial pain
 - Sitting
- Spontaneous
 - 9 months
- Hysteroscopy
- Vulval biopsy
- Simple ovarian cyst

31

WHRIA



A: Ilio-inguinal, Ilio hypogastric, Genitofemoral nerves
 B: Pudendal nerve
 C: Inferior Cluneal nerve

WHRIA Case 3: Helen

History

- Sjogren's
- Alcohol
- Endone
 - Unintentional overdose
- Music
- Port Macquarie

33

WHRIA Case 3: Helen

Examination

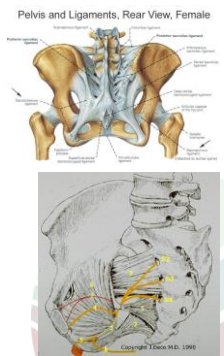
- Distressed
- MMSE
- Romberg's positive
- Punctate allodynia right labia
- Levator myalgia

34

WHRIA Case 3: Helen

Management

- Neurology
- Rheumatology
- Pudendal nerve block
 - Transgluteal



35

WHRIA Case 3: Helen

Criteria of Nantes

- Pain in distribution of pudendal nerve
- Pain worse with sitting
- No pain at night
- No sensory impairment
- Pain relieved by pudendal nerve bl

Labat J et al 2008

36

WHRIA
Western Health Research Institute of Australia

Case 3: Helen

Management

- On mirtazepine
 - Tricyclic?
 - SNRI?
 - Sjogren's
- Buprenorphine
- Gabapentinoid
- Valproate

37

WHRIA
Western Health Research Institute of Australia

Case 3: Helen

Management

- Physiotherapy
 - Sit cushion
 - Limited self management
- Psychology
 - Pacing
 - Catastrophisation

38

WHRIA
Western Health Research Institute of Australia

Case 3: Helen

Progress

- Pudendal nerve block
 - Positive
 - 1 week
 - Repeat

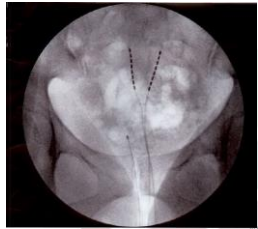
39

WHRIA
Western Health Research Institute of Australia

Case 3: Helen

Progress

- Neuromodulation
 - Sacral
 - Pudendal



40

WHRIA
Western Health Research Institute of Australia

41

WHRIA
Western Health Research Institute of Australia

Challenge

- Central mechanisms
- Peripheral triggers
 - Visceral
 - Pelvic floor
 - Pelvic girdle
 - Nerves
- Psychological effects
- Functional effects

42



WHRIA

Case 4

Ruby

- 32yo
- Urinary tract infection
 - Treated
- Recurrent
 - MSU?
 - Pain provokes voiding
 - Frequency, urgency, nocturia

45

A slide with the WHRIA logo in the top left corner and the text "Case 4" in the top right corner. The main content area contains the name "Ruby" and a bulleted list of clinical details. The slide has a decorative border on the left and bottom right.