

 **WHRIA**
Women's Health & Research Institute of Australia

**Pelvic and Perineal Pain:
Beyond Endometriosis**


Jason Chow


 


 **WHRIA**
Women's Health & Research Institute of Australia

Heartsink!

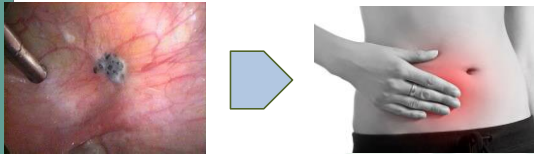



 **WHRIA**
Women's Health & Research Institute of Australia

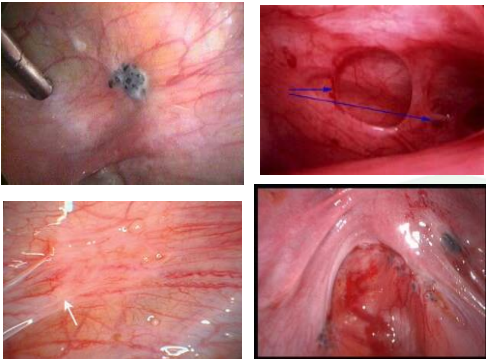



 **WHRIA**
Women's Health & Research Institute of Australia

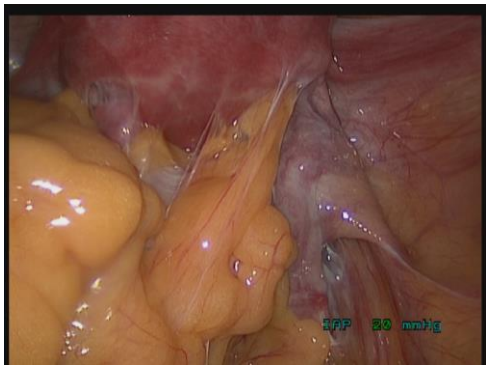
Background



 **WHRIA**
Women's Health & Research Institute of Australia




 **WHRIA**
Women's Health & Research Institute of Australia



WHRIA

Surgery

- 20% no response to surgery
- 32% placebo response



Abbott et al 2004

- 1st surgery 83% reduction in pain
- 2nd surgery 53% reduction in pain

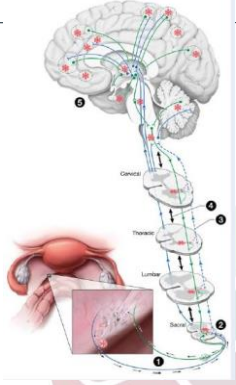
- 20% recurrence disease

Vercellini et al 2009

WHRIA

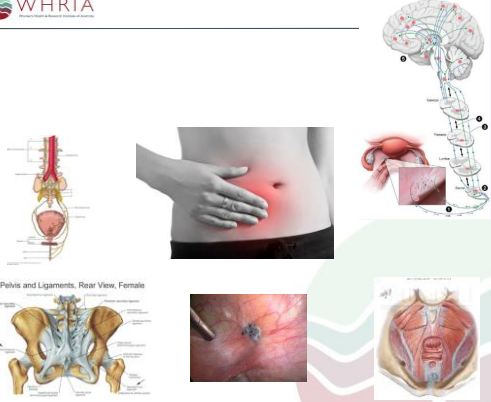
More...

- Nerve fibres
- Sensitisation
 - Cross sensitisation
 - Central sensitisation
- Progestagens
 - Anti-angiogenic
 - Anti-inflammatory
 - Immunomodulatory



Stratton and Berkley 2011
Fenton 2007

WHRIA



Pelvis and Ligaments, Rear View, Female

WHRIA

Challenge

- Central mechanisms
- Peripheral triggers
 - Not just visceral based
- Psychological effects
- Functional effects

WHRIA

2 Clinical Settings

- More than endometriosis
- Vaginal pain

WHRIA

Case 1

Natalie

- 25yo
- G0
- Dysmenorrhoea
- Non menstrual pelvic pain
- Dyschezia
- Chronic neck pain
 - Work - Bunning's
- Same sex
 - No current partner
- Ultrasound - normal

WHRIA Case I: Natalie

Assessment

- Normal neurological exam
- Pelvic girdle changes
- Abdominal wall hyperaesthesia

WHRIA

Werner et al 2013

WHRIA Case I: Natalie

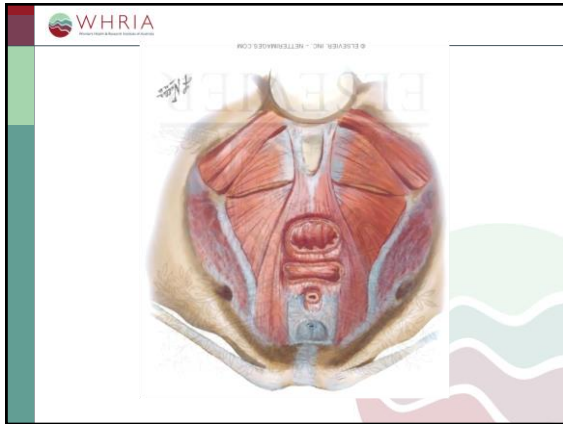
Assessment

- Normal neurological exam
- Pelvic girdle changes
- Abdominal wall hyperaesthesia
- Hypo oestrogenic vulva and vagina?
- High tender cul de sac
- Pelvic floor myalgia

WHRIA

WHRIA

WHRIA



WHRIA Case I: Natalie

Management

- Amitriptyline
- NSAIDs
- COCP

WHRIA Case I: Natalie

Pharmacotherapy

- Tricyclic antidepressants
 - Amitriptyline
 - Nortriptyline
 - Less sedation, adverse symptoms
 - Imipramine
- 2 hours before bed
- 5mg → 10mg → 20mg → ... → 50mg
- Weekly titration

WHRIA Case I: Natalie

Pharmacotherapy

- SNRI
 - Duloxetine
 - (Venlafaxine)
- Morning
- 30mg → 60mg → ...
- Week to fortnight titration

22

WHRIA Case I: Natalie

Pharmacotherapy

- Gabapentinoids
 - Gabapentin
 - Pregabalin

Gabapentin	Mane	Midi	Nocte
Week 1			100mg
Week 2			200mg
Week 3	200mg		200mg
Week 4	200mg	200mg	200mg
Week 5	200mg	200mg	400mg

WHRIA Case I: Natalie

Management


- Amitriptyline
- NSAIDs
- COCP
- Physiotherapy
- Internet based CBT
- Laparoscopy

WHRIA
Western Health Research Institute of Australia

Case 1: Natalie

Management

- Improvement
 - Dysmenorrhoea
 - NMPP
 - Neck pain
- Dyschezia predominant
- Laparoscopy
 - Stage 3 endometriosis
 - Pararectal space
 - Weaning Endep at 6 months
 - Physiotherapy



WHRIA
Western Health Research Institute of Australia

26




WHRIA
Western Health Research Institute of Australia

Case 2

Helen

- 68yo
- Right labial pain
 - Sitting
- “Spontaneous”
 - UTI
 - 9 months
- Pelvic ultrasound normal
- Hysteroscopy
- Vulval biopsy



WHRIA
Western Health Research Institute of Australia

Case 2: Helen

History

- Alcohol
- Endone
 - Unintentional overdose
- Music




WHRIA
Western Health Research Institute of Australia

Case 2: Helen

Examination

- Distressed
- Depressed
- Neurological exam
- Punctate allodynia right labia
- Levator myalgia




WHRIA
Western Health Research Institute of Australia

Case 2: Helen

Assessment and Management

- Vaginal pain
 - Dermatoses
 - Levators
 - Pelvic girdle
 - Pudendal nerve
 - Central mechanisms
- Depression
- Coping strategies
- Opioid risks



WHRIA
Western Health Research Institute of Australia

Case 2: Helen

Management

Adjuncts:

- On mirtazepine
 - Tricyclic?
 - SNRI?
- Gabapentinoid

Long-acting opioids:

- Buprenorphine?
 - Patch
- Tapentadol?

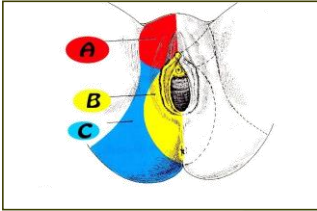
WHRIA
Western Health Research Institute of Australia

Case 4: Helen

Management

- Physiotherapy
 - Sit cushion
 - Limited self management
- Psychology
 - Pacing
 - Catastrophisation

WHRIA
Western Health Research Institute of Australia



A: Ilio-inguinal, Ilio hypogastric, Genito-femoral nerves
B: Pudendal nerve
C: Inferior Cluneal nerve

WHRIA
Western Health Research Institute of Australia

Case 2: Helen

Criteria of Nantes

- Pain in distribution of pudendal nerve
- Pain worse with sitting
- No pain at night
- No sensory impairment
- Pain relieved by pudendal nerve block

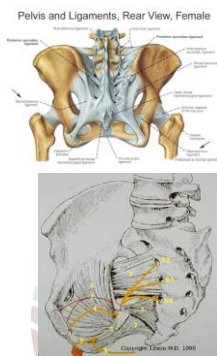
Labat J et al 2008

WHRIA
Western Health Research Institute of Australia

Case 2: Helen

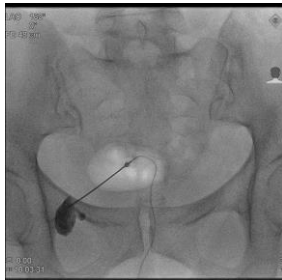
Management

- MRI
- Pudendal nerve block
 - Transgluteal



Pelvis and Ligaments, Rear View, Female


WHRIA
Western Health Research Institute of Australia



WHRIA Case 2: Helen


Management

- Pudendal nerve release surgery
- Botulinum toxin pelvic floor



WHRIA Botulinum toxin

- 2 years chronic pelvic pain
- Non menstrual pelvic pain
- Dyspareunia
- Adjunct to
- Adverse effects
 - Reaction
 - Prolapse
 - Incontinence
 - Tachypnea




WHRIA Case 2: Helen

Management




- Pudendal nerve release surgery
- Botulinum toxin pelvic floor
- Neuromodulation
 - Sacral
 - Pudendal

WHRIA



Armstrong and Vancallie 2016

WHRIA

- 
 Pudendal nerve
 Botulinum toxin
 Neuromodulation
- 
 Patient information
- 
 Opioid calculator

WHRIA Challenge

- Central mechanisms
- Peripheral triggers
 - Not just visceral based
- Psychological effects
- Functional effects

